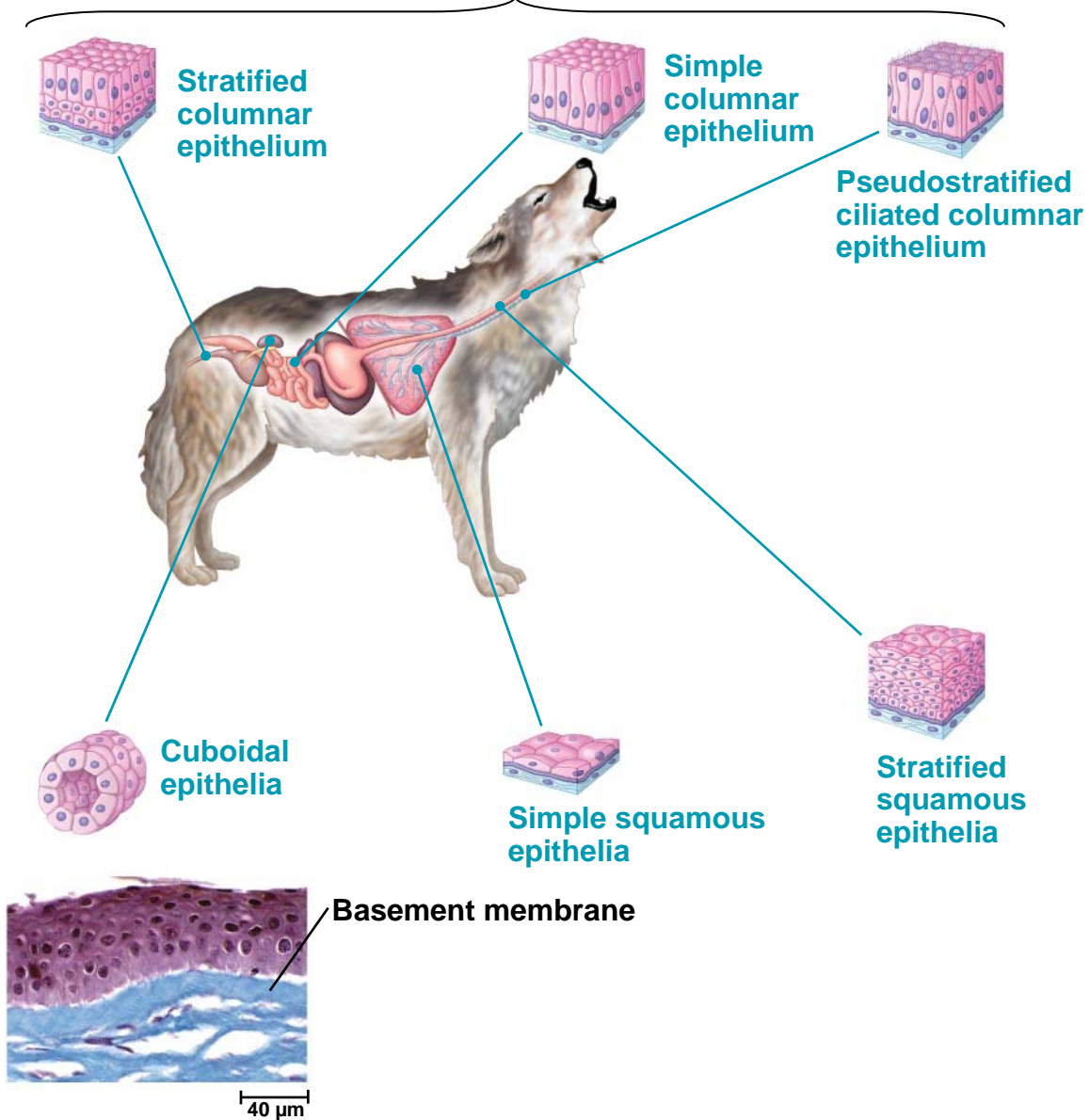
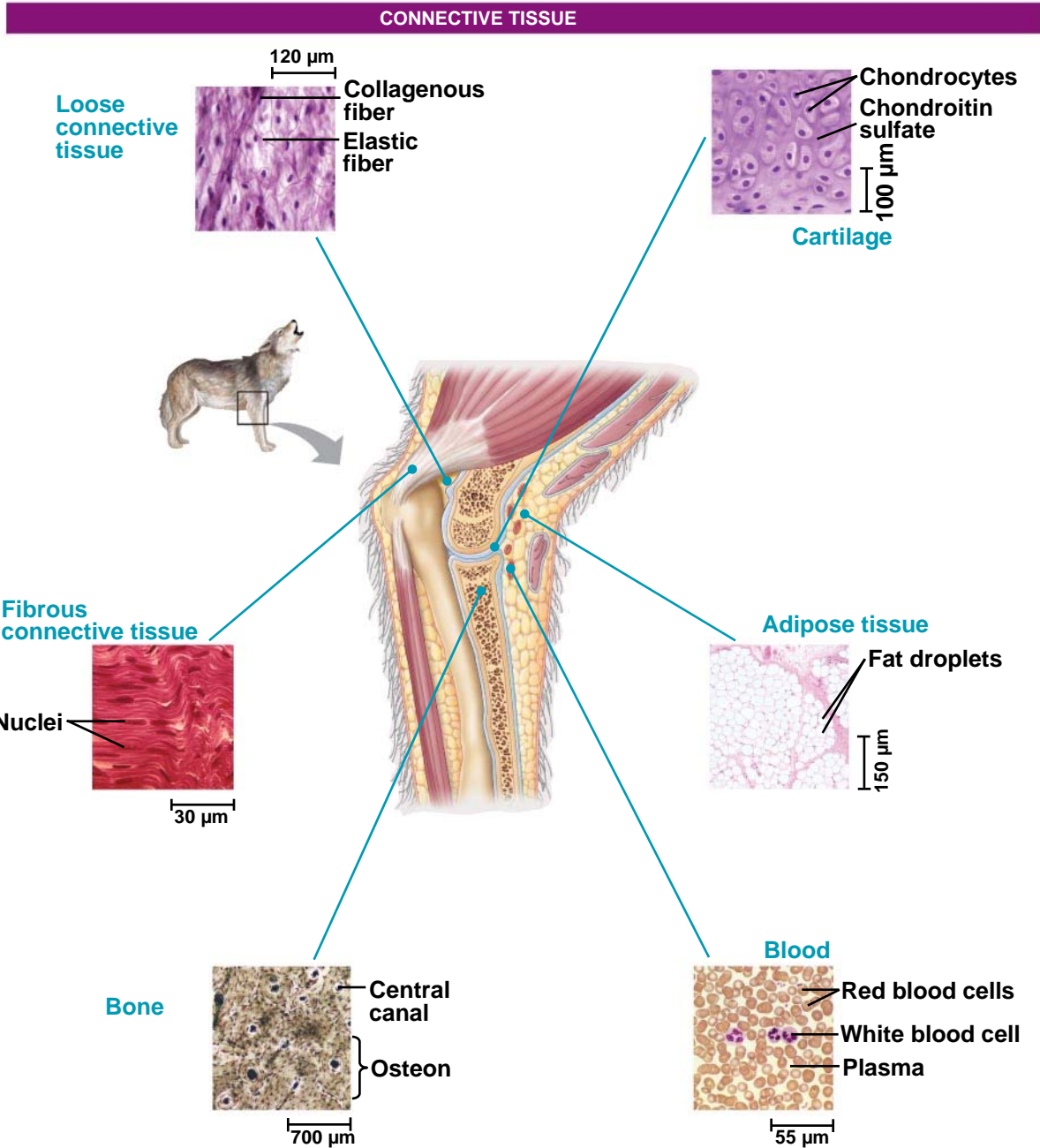


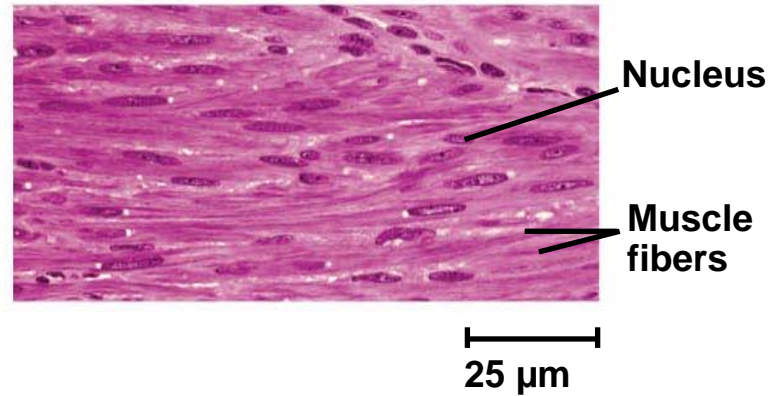
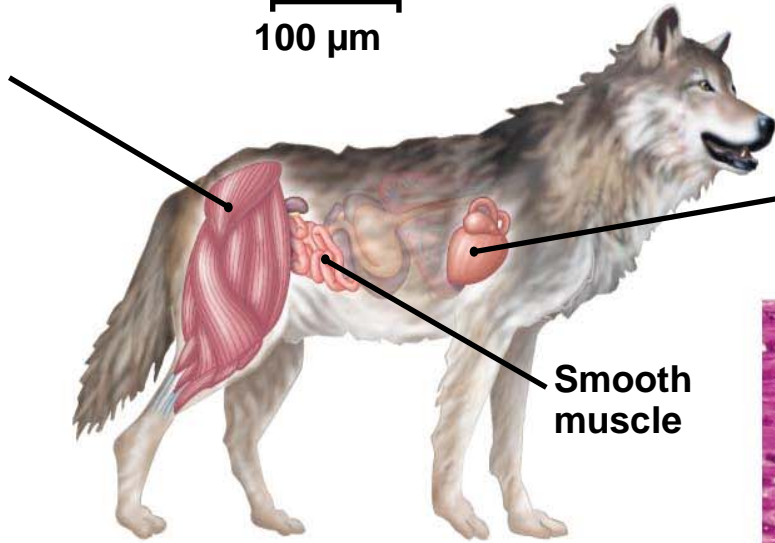
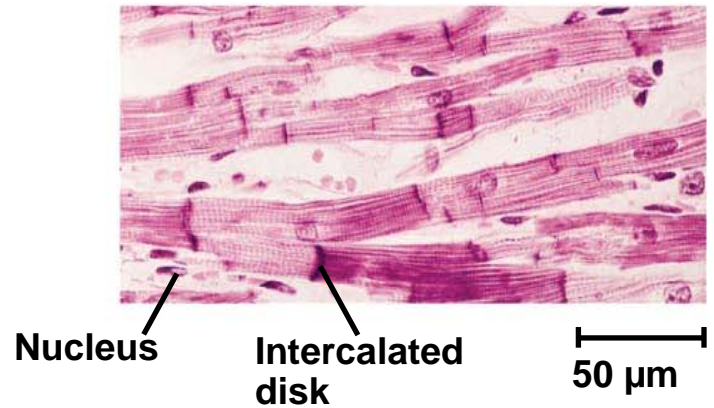

EPITHELIAL TISSUE

Columnar epithelia, which have cells with relatively large cytoplasmic volumes, are often located where secretion or active absorption of substances is an important function.






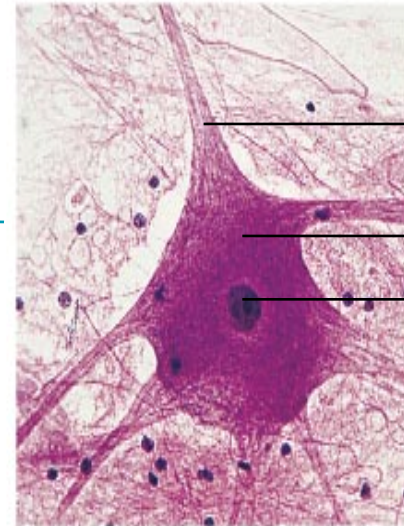
Muscle Tissue



NERVOUS TISSUE



Neuron



Process

Cell body

Nucleus

50 μ m